



PATIENT	PRESENTING CLINICAL SIGNS
Manook Chin	Clinical Exam Findings: NSF ABNORMAL Labwork Values ALP ~230 in Feb 2025; increased to 291 in Dec 2025 Current Medications Liver protectants (SAME and Silymarin) Radiographic Findings none
SPECIES	ULTRASONOGRAPHIC EXAMINATION OF THE ABDOMEN
Canine	Urinary System
BREED	The urinary bladder, trigone, cystourethral junction, and visible pelvic urethra to a depth of 3 cm exhibited normal thickness and tone. Anechoic urine was present in the lumen with no evidence of urine/lumen sediment, mineral, or calculi. The ureteral papillae were normal. The ureters were not visible which is normal. No evidence of inflammatory or neoplastic changes was noted.
Husky	
SEX	Normal size and margination were present in the kidneys. A normal 1:3 cortex / medulla ratio was maintained. The medulla and cortices were uniform in texture with some increased echogenicity and mild loss of corticomedullary symmetry and definition expected for the age of the patient. No evidence of pelvic dilation was present. Areas of mild medullary mineral were present in the right kidney. The left kidney measured 8.0 cm in length. The right kidney measured 7.7 cm in length.
MN	
AGE	The area of the aortic trifurcation was free of pathology.
11yr	The area of the residual prostate appeared normal and free of pathology.
WEIGHT	Adrenal Glands
88lb	The left adrenal gland was uniform in size and contour with a uniformly hypoechoic parenchyma. The left adrenal gland measured 0.82 cm width at the caudal pole. The right adrenal gland was indistinctly visualized with no overt pathology subjectively measuring 0.82 cm in width at the caudal pole.
INTERPRETED BY	Spleen
R. McKenzie Daniel, DVM, DABVP (Canine and Feline)	The spleen exhibited primarily finely textured and homogenous parenchyma which was hyperechoic to the liver and renal cortical parenchyma. Small intermittent symmetrical, echogenic nodules were present throughout the perihilar parenchyma. The capsule was smooth and regular without apparent expansion. The splenic vasculature at the hilus was normal in volume with no evidence of congestion or thrombosis. Acute to chronic inflammatory or neoplastic changes were not noted. The echogenic nodules tend to trend benign and are most consistent with benign hyperplasia or myelolipomas.
IMAGING PERFORMED BY	Liver/Gallbladder
Sara Hansen	The liver was subjectively normal in size, structure, and contour. The liver parenchyma was uniform and hypoechoic to the spleen with a mild coarse echotexture. Normal vascular volume. The hepatic and portal vasculature were normal in appearance without signs of congestion. The gallbladder was non-distended in size with thin walls and primarily anechoic luminal content. The cystic and common bile ducts were normal.
HOSPITAL NAME	Gastrointestinal
Q Street Animal Hospital	The stomach presented intact wall layering with a normal wall layer ratio. The lumen of the stomach was empty with no signs of ileus, obstruction or foreign material.
REFERRING VET	The small intestine presented intact wall layering with 1:3 muscularis/mucosa ratio. The lumen of the small intestine was empty with no signs of mechanical/metabolic ileus, obstruction or foreign material.
Dr Renesma	
INVOICE	
23370	
DATE	
12/29/2025	



PATIENT

Normal visible colon wall layers were present with apparent formed feces in lumen.

Manook Chin

Pancreas

The area of the pancreas was sonographically normal.

SPECIES

Free Abdomen

Canine

No omental masses, overt lymphadenopathy or peritoneal effusion was present.

BREED

ULTRASONOGRAPHIC FINDINGS

Husky

Primary

- Sonographically normal liver / gallbladder-consistent with mild benign hepatopathy.
- Small benign splenic nodules - most consistent with probable myelolipomas.
- Age-related renal changes.
- Normal bilateral adrenal glands.

SEX

MN

AGE

INTERPRETATION OF THE FINDINGS & FURTHER RECOMMENDATIONS

11yr

No evidence of significant visceral pathology with a largely mild geriatric abdomen. Mildly progressive idiopathic vacuolar hepatopathy is suspected. No overt evidence of adrenal disease as a contributing factor in conjunction with lack of reported clinical signs.

WEIGHT

88lb

Assuming the patient is non-clinical, continued hepatosupportive medications with clinical monitoring is recommended. Sonographic reassessment indicated if progressive hepatopathy, evidence of cholestasis or if clinical signs consistent with hepatic or adrenal disease arise.

INTERPRETED BY

R. McKenzie Daniel,
DVM, DABVP
(Canine and Feline)

IMAGING PERFORMED BY

Sara Hansen

HOSPITAL NAME

Q Street Animal
Hospital

REFERRING VET

Dr Renesma

INVOICE
23370

DATE
12/29/2025



PATIENT

Manook Chin

SPECIES

Canine

BREED

Husky

SEX

MN

AGE

11yr

WEIGHT

88lb

INTERPRETED BY

R. McKenzie Daniel,
 DVM, DABVP
 (Canine and Feline)

IMAGING PERFORMED BY

Sara Hansen

HOSPITAL NAME

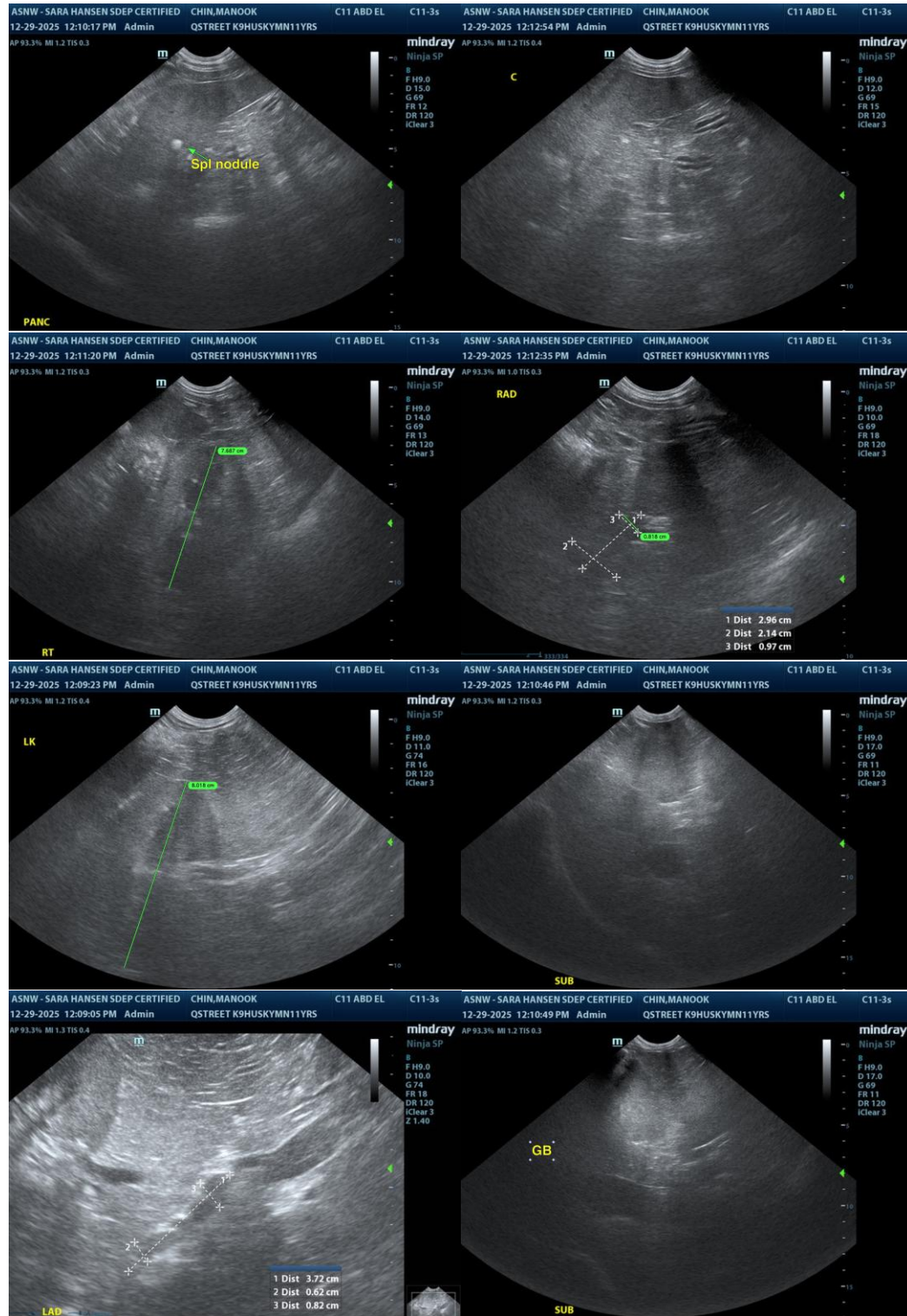
Q Street Animal
 Hospital

REFERRING VET

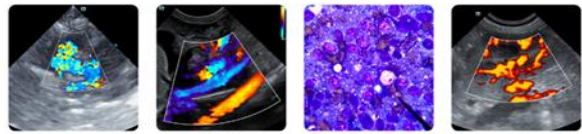
Dr Renesma

INVOICE
 23370

DATE
 12/29/2025



The information and recommendations provided are based on the images presented by the referring veterinarian/sonographer. No evaluation can be communicated regarding pathology that was not



PATIENT

Manook Chin

visible in the image/video clips provided.

Thank you for this referral. If the clinical or image interpretation does not parallel your findings or if I can be of any further assistance, please contact me.

SPECIES

Canine

R. McKenzie Daniel, DVM, DABVP (Canine/Feline Practice)
info@sonopath.com

BREED

Husky

SEX

MN

AGE

11yr

WEIGHT

88lb

INTERPRETED BY

R. McKenzie Daniel,
DVM, DABVP
(Canine and Feline)

IMAGING PERFORMED BY

Sara Hansen

HOSPITAL NAME

Q Street Animal
Hospital

REFERRING VET

Dr Renesma

INVOICE

23370

DATE

12/29/2025